

THE VALUE OF HIGH-RESOLUTION T2-WEIGHTED MRI TO EVALUATE LOCAL STAGING OF RECTAL CANCER

*Pham Thi Men**, *Tran Duc Huy**,
*Le Van Khang***, *Vu Dang Luu***

SUMMARY

Purpose: To describe imaging characteristics of rectal cancer on high-resolution T2-weighted MRI in predicting local staging of rectal cancer

Materials and methods: A cross-sectional descriptive study aimed at evaluating the sensitivity, specificity, accuracy, and correlation coefficient of MRI in staging T (tumor) and N (lymph node involvement) in patients with rectal cancer. The study used a high-resolution T2 weighted on 3 Tesla MRI to assess the pre-treatment stage compared with histopathology results after surgery.

Results: The study involved a sample of 48 patients, consisting of 27 men and 21 women. The pre-treatment stage was assessed using magnetic resonance imaging (MRI), considering stages as T1, T2, T3, and T4 were 2 (4.2%), 6 (12.5%), 36 (75%) and 4 (8.3%); staged as N0, N1, N2 were 19 (39.6%), 17 (35.4%), 4 (8.3%). A total of 21 patients underwent surgical procedures, and this study aimed to evaluate the sensitivity, specificity, and accuracy of MRI with a high-resolution T2 weighted in comparison to the overall postoperative pathology were 100%, 75%, 90.5% for T1-3 staging and 75%, 76.92%, 76.19% for N0-2 staging. The κ values were 0.714 and 0.199 for T1-3 and N0-2 staging, respectively.

Conclusion: MRI with a high-resolution T2 weighted has significant value in the diagnosis of local staging of rectal cancer, particularly in determining the T stage. The precise local staging plays a crucial role in selecting the appropriate treatment methods, and prolongation of survival time for individuals with rectal cancer.

Keywords: *Rectal cancer staging; Magnetic resonance imaging 3 Tesla; High-resolution T2-weighted.*

* Hanoi Medical University

** Radiology Center, Bach Mai Hospital, Hanoi, Vietnam

I. INTRODUCTION

Rectal cancer is one of the most common cancers in Vietnam and worldwide. In Vietnam, rectal cancer ranks as the fifth most commonly diagnosed cancer and the sixth leading cause of cancer-related deaths. The overall 5-year survival rates for rectal cancer are more than 90% in stage I, 70% to 85% in stage II, 25% to 80% in stage III, but less than 10% in stage IV [1]. Therefore, it is essential to accurately assess the stage of the disease to guide appropriate treatment decisions and improve patient outcomes.

Magnetic resonance imaging (MRI) is a widely used and non-invasive assessment of rectal cancer. MRI provides valuable information about the depth of invasion of the tumor, the number of involved lymph nodes, and other important factors that help in determining the optimal treatment plan. By accurately assessing these parameters, the doctor can make informed decisions to increase the survival rate and prognosis, as well as reduce the risk of local recurrence.

Studies have been published in recent years on the MRI to diagnose rectal cancer and updated recommendations from the 2016 European Society of Gastrointestinal and Abdominal Radiology (ESGAR) consensus meeting about the value of MRI in evaluating rectal cancer have found an important role and value in high resolution T2-Weighted. While there have been foreign studies on the value of high-resolution T2-weighted MRI in assessing the local stage of rectal cancer, it is noteworthy that there is currently no study on this specific sequence in my country. Therefore, I conducted a study to evaluate the value of high-resolution T2 weighted in assessing the local stage of rectal cancer when compared with postoperative pathology results.

II. MATERIALS AND METHODS

1. Materials

The study was conducted on patients who had a confirmed diagnosis of rectal cancer based on histopathology results. These patients underwent pelvic MRI with high-resolution T2-weighted imaging on 3 Tesla MRI scanners at Bach Mai Hospital. It is important to note that patients who did not undergo pelvic MRI with high-

resolution T2-weighted imaging on a 3 Tesla scanner and/ or had previously received treatment were excluded from the study. This exclusion criterion helps ensure that the study focuses on a specific group of patients and reduces potential confounding factors that could affect the results.

2. Methods

A cross-sectional descriptive study conducted at the Radiology Center, Bach Mai Hospital from March 2022 to September 2023 involved 48 patients. The magnetic resonance machine used for the study was the GE Signa Architect (GE Healthcare, USA).

The data collected was entered and analyzed using descriptive statistical methods on SPSS 20.0. The results of the study were presented through tables and charts.

2.1. Prepare the patient

To prepare for the scan, please instruct the patient to clean the enema before the procedure. It is important to explain the process clearly to ensure the patient understands and can coordinate well during the scan.

2.2. MRI parameters

The scan will utilize a high-resolution T2 pulse sequence with the following specifications: In-plane resolution: 0.6x0.6mm; Slice thickness: 3mm; Voxel size: 1.08mm³; Field of view: 160mm; Matrix size: 256x256; Averaged signals: Four; TR/TE: 4750/95

2.3. Evaluate images and process data

The images were analyzed by radiologists with at least five years of experience reading pelvic and rectal MRI films.

The variables of the study included age, gender, and imaging characteristics of rectal cancer: T invasion (according to the AJCC eighth edition). Characteristics of lymph nodes suspected of metastasis: lymph node shape, lymph node signal, lymph node size. Access MRF (mesorectal fascia), and EMVI (extramural vascular invasion) on magnetic resonance.

The study also looked at the results of postoperative pathology in patients who were eligible for surgery. It compared these results to the value calculated from the high-resolution T2 weighted in assessing the local stage of rectal cancer.

III. RESULTS

The study involved 48 patients, the age range was 32-85 years, and the mean age was 64.5 years. Twenty-seven (56,3%) of 48 patients were men with a male-to-female ratio of 1.3:1. The main reason for hospital admission was bloody stools and weight loss, and the most common location of rectal cancer was in the middle rectum, accounting for 56.3%. The pre-treatment stage was assessed using magnetic resonance imaging (MRI), considering stages as T1, T2, T3, T4 were 2 (4.2%), 6 (12.5%), 36 (75%) and 4 (8.3%); staged as N0, N1, N2 were 19 (39.6%), 17 (35.4%), 4 (8.3%). staged as N0, N1, N2 were 19 (39.6%), 17 (35.4%), 4 (8.3%). A total of 21 patients underwent surgical procedures, and this study aimed to evaluate the sensitivity, specificity, and accuracy of MRI with a high-resolution T2 weighted in comparison to the overall postoperative pathology were 100%, 75%, 90.5% for T1-3 staging and 75%, 76.92%,

76.19% for N0-2 staging. Thek values were 0.714 and 0.199 for T1-3 and N0-2 staging, respectively.

All surgery cases had no invasion of the MRF, consistent with the preoperative diagnosis. The sensitivity, specificity, and accuracy of the magnetic resonance with EMVI were 66.67%, 100%, and 95.2%.

The results were presented in detail through tables.

1. Gender

The study involved 48 patients, 27 patients were men (56.3%) higher than the women. The male-to-female ratio of 1.3:1.

2. Age

The study involved 48 patients has an age range was 32-85 years, and the mean age was 64.5 years, of which 75% of cases were over 54 years, and 25% of cases were over 70 years.

3. Comparison of local staging between MRI and pathology

Table 1. Comparison of Tumor (T) staging between MRI and pathology

MRI \ Pathology	T1	T2	T3	Total	Sn (%)	Sp (%)	Acc (%)
T1	2	0	0	2	66,7	100	95,2
T2	1	3	0	4	60	93,4	85,7
T3	0	2	13	15	10	75	90,5
Total	3	5	13	21			

Comment: The overall MRI accuracy for each T stage was 90.5%. The accuracy of each T stage was 95,2% for T1, 85,7% for T2, and 90,5% for T3.

4. Comparison of Nodal (N) Staging between MRI and Pathology

Table 2. Nodal (N) Staging between MRI and Pathology

MRI \ Pathology	Yes	No	Total	Sn (%)	Sp (%)	Acc (%)
Yes	2	0	2	66,7	100	95,2
No	1	18	19			
Total	3	18	21			

Comment: The overall MRI accuracy for each N stage was 76.19%. The accuracy of each Nstage was 85.7% for N0, 66.7% for N1, 81.0% for N2.

Table 3. Comparison of extramural vascular invasion Staging between MRI and Pathology

MRI \ Pathology	N0	N1	N2	Total	Sn (%)	Sp (%)	Acc (%)
No	10	2	0	12	76,9	100	85,7
N1	3	1	2	6	20	81,3	66,7
N2	0	2	1	3	33,3	88.9	81
Total	13	5	3	21			

Comment: The accuracy of extramural vascular invasion (EMVI) was 95.24%

IV. DISCUSSION

The purpose of our study was to determine the efficacy of 3T MRI in staging rectal cancer with histopathologic staging as the criterion standard and to compute the accuracy of MRI in the prediction of extramural spread and metastatic adenopathy.

In our study, 12.5% of tumors were T1 and T4 lesions, 12.5% were T2 lesions, and 75% were T3 lesions. The Mercury group [2] reported that 45% of their patients had T3 disease, 18% had T2 disease, 8% had T1 disease, and 6% had T4 disease. In the series by Brown et al [3], no patients had T1 disease, 64% had T3 disease, 17% had T2 disease, and 7% had T4 disease. We, therefore, found a higher distribution of T3 disease.

The accuracy of MRI for T staging of rectal cancer ranged from 67% to 83% [4–7] which mainly depended on the difficulty in differentiating between T1 and T2 tumors as well as T2 tumors to be misdiagnosed as T3 tumors [8].

Brown et al. [3] demonstrated 100% accuracy in T staging of 28 primary rectal cancers using high-resolution images. Poon et al. [9] reported an overall accuracy of 74% using the similar technique. Rao et al. [10] showed that the overall accuracy was 85.1% for T staging. Our study showed that the total accuracy of T1–3 staging by MRI was 90.5%. The Kappa value for T1–4 staging was 0.714, indicating substantial agreement with the histopathologic results. Our results suggest that MRI has become one of the most accurate T-staging modalities for rectal cancer.

Overall, MR tended to be less accurate for N staging of rectal cancer than for T staging. In our study, the overall MR accuracy for all N0, N1, and N2 stages was 76.19%. The Kappa value for all N stages was only 0.199, indicating low agreement with the histopathologic results. Therefore, detecting lymph node metastases is difficult.

With studies performed according to old pulse sequences, the sensitivity and specificity of MRI for T staging of the tumor varies considerably, with a sensitivity that ranges from 29% to 57% and a specificity that ranges from 50% to 83% [3], [9], [11], [12]. Takayki Akasu et al. studied the value of high-resolution magnetic resonance imaging for preoperative evaluation of rectal cancer. According to the study, the accuracy, sensitivity, and specificity for T staging were 96%, 96%, and 96%. For N staging, the accuracy, sensitivity, and specificity were 74%, 87%, and 87% [2]. Moreover, the diagnostic sensitivity and specificity of MRI are also largely dependent on the experience of the radiologists. Thus, the results differ greatly among different institutes worldwide.

In summary, in our study sensitivity, specificity, PPV, and NPV of 3T MRI for prediction of extramural tumor spread were 100%, 75%, and 90.5%. The sensitivity, specificity, PPV, and NPV of 3T MRI for the prediction of metastatic adenopathy were 75%, 76.92%, and 76.19%. This study shows that MRI is unlikely to miss any significant parameter in the staging of rectal carcinoma.

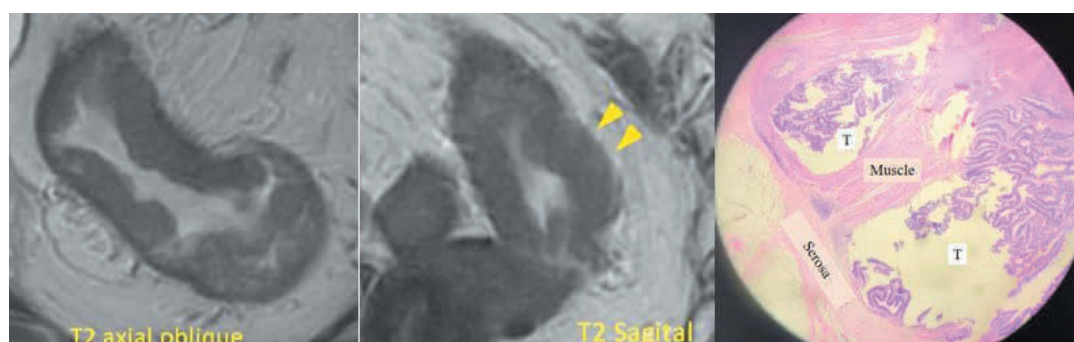
V. CONCLUSION

MRI with high-resolution T2-weighted enables a

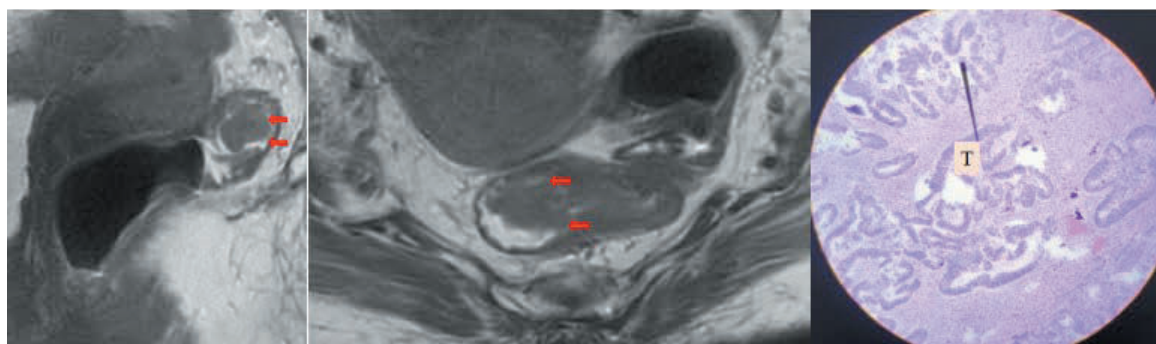
preoperative assessment of the T stage of rectal cancer with high accuracy. However, it suggests that the assessment of the N stage using this technique is only fairly accurate. The study also indicates that MRI hardly misses any important parameters in diagnosing the

stage of rectal cancer, which is promising for decision-making. Nevertheless, further studies involving larger samples from multiple medical centers are necessary to validate these findings and ensure their reliability and generalizability.

SOME CASE STUDIES IN OUR RESEARCH



Case 1: A 66-year-old female patient with mid-segment rectal carcinoma showed an image of the cancer in the mid-segment of the rectum. The MRI indicated some continuous loss of the muscle layer (arrow), but no invasion through the perirectal fat layer, suggesting a full-thickness T2/T3a stage. The post-operative pathology result revealed that the tumor did invade the perirectal fat layer, corresponding to stage T3.



Case 2: A 75-year-old female patient with high-segment rectal carcinoma showed an image of the cancer in the high-segment rectum. The MRI indicated the tumor was located in the submucosal layer suggesting the T1 stage. The post-operative pathology result confirmed that the tumor had indeed invaded the submucosal layer, corresponding to stage T1.

REFERENCES

1. Hong, Y.; Kim, J.; Choi, Y. J.; Kang, J. G. Clinical Study of Colorectal Cancer Operation: Survival Analysis. *Korean J Clin Oncol* 2020, 16 (1), 3–8. <https://doi.org/10.14216/kjco.20002>.
2. Akasu, T.; Iinuma, G.; Takawa, M.; Yamamoto, S.; Muramatsu, Y.; Moriyama, N. Accuracy of High-Resolution Magnetic Resonance Imaging in Preoperative Staging of Rectal Cancer. *Ann Surg Oncol* 2009, 16 (10), 2787–2794. <https://doi.org/10.1245/s10434-009-0613-3>.

3. *Brown: Rectal carcinoma: thin-section MR imaging... - Google Scholar.* https://scholar.google.com/scholar_lookup?title=Rectal%20carcinoma%3A%20thin-section%20MR%20imaging%20for%20staging%20in%2028%20patients&publication_year=1999&author=G.%20Brown&author=C.J.%20Richards&author=R.G.%20Newcombe (accessed 2023-07-29).
4. Rovera, F.; Dionigi, G.; Boni, L.; Cutaia, S.; Diurni, M.; Dionigi, R. The Role of EUS and MRI in Rectal Cancer Staging. *Surg Oncol* 2007, 16 Suppl 1, S51-52. <https://doi.org/10.1016/j.suronc.2007.10.038>.
5. Suzuki, C.; Torkzad, M. R.; Tanaka, S.; Palmer, G.; Lindholm, J.; Holm, T.; Blomqvist, L. The Importance of Rectal Cancer MRI Protocols on Interpretation Accuracy. *World J Surg Oncol* 2008, 6, 89. <https://doi.org/10.1186/1477-7819-6-89>.
6. Torkzad, M. R.; Hansson, K. A.; Lindholm, J.; Martling, A.; Blomqvist, L. Significance of Mesorectal Volume in Staging of Rectal Cancer with Magnetic Resonance Imaging and the Assessment of Involvement of the Mesorectal Fascia. *Eur Radiol* 2007, 17 (7), 1694–1699. <https://doi.org/10.1007/s00330-006-0521-x>.
7. Videhult, P.; Smedh, K.; Lundin, P.; Kraaz, W. Magnetic Resonance Imaging for Preoperative Staging of Rectal Cancer in Clinical Practice: High Accuracy in Predicting Circumferential Margin with Clinical Benefit. *Colorectal Dis* 2007, 9 (5), 412–419. <https://doi.org/10.1111/j.1463-1318.2006.01167.x>.
8. *Sethi: Contemporary coloproctology - Google Scholar.* https://scholar.google.com/scholar_lookup?title=Contemporary+coloproctology&author=R+Sethi&author=SH.+Lee&publication_year=2012& (accessed 2023-07-29).
9. Poon, F. W.; McDonald, A.; Anderson, J. H.; Duthie, F.; Rodger, C.; McCurrach, G.; McKee, R. F.; Horgan, P. G.; Foulis, A. K.; Chong, D.; Finlay, I. G. Accuracy of Thin Section Magnetic Resonance Using Phased-Array Pelvic Coil in Predicting the T-Staging of Rectal Cancer. *Eur J Radiol* 2005, 53 (2), 256–262. <https://doi.org/10.1016/j.ejrad.2004.03.011>.
10. Rao, S.-X.; Zeng, M.-S.; Xu, J.-M.; Qin, X.-Y.; Chen, C.-Z.; Li, R.-C.; Hou, Y.-Y. Assessment of T Staging and Mesorectal Fascia Status Using High-Resolution MRI in Rectal Cancer with Rectal Distention. *World J Gastroenterol* 2007, 13 (30), 4141–4146. <https://doi.org/10.3748/wjg.v13.i30.4141>.
11. Beets-Tan, R. G.; Beets, G. L.; Vliegen, R. F.; Kessels, A. G.; Van Boven, H.; De Bruine, A.; von Meyenfeldt, M. F.; Baeten, C. G.; van Engelshoven, J. M. Accuracy of Magnetic Resonance Imaging in Prediction of Tumour-Free Resection Margin in Rectal Cancer Surgery. *Lancet* 2001, 357 (9255), 497–504. [https://doi.org/10.1016/s0140-6736\(00\)04040-x](https://doi.org/10.1016/s0140-6736(00)04040-x).
12. Brown, G.; Radcliffe, A. G.; Newcombe, R. G.; Dallimore, N. S.; Bourne, M. W.; Williams, G. T. Preoperative Assessment of Prognostic Factors in Rectal Cancer Using High-Resolution Magnetic Resonance Imaging. *Br J Surg* 2003, 90 (3), 355–364. <https://doi.org/10.1002/bjs.4034>.

Correspondent: Pham Thi Men. Email: mennt46@gmail.com

Received: 30/08/2023. Assessed: 30/08/2023. Accepted: 08/12/2023